

M. Scheuermann

# M. Scheuermann

juvenile dorsal kyphosis

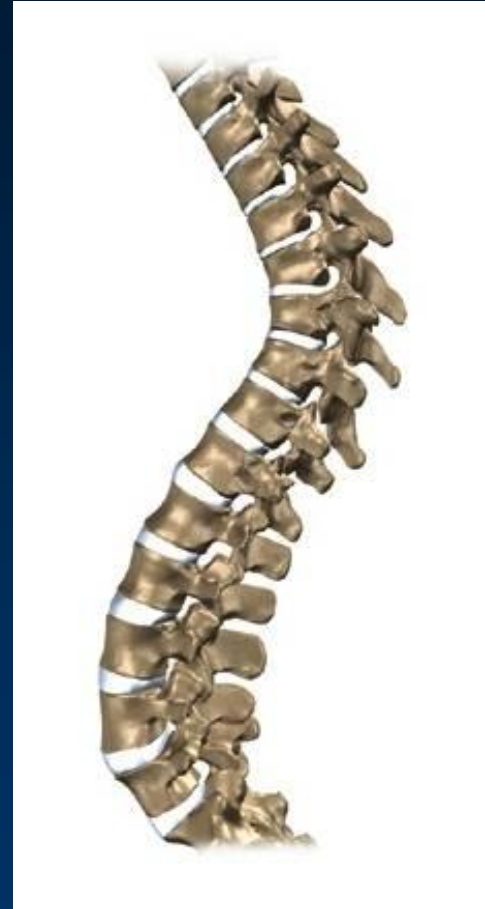up to 8% of population

Etio: unclear

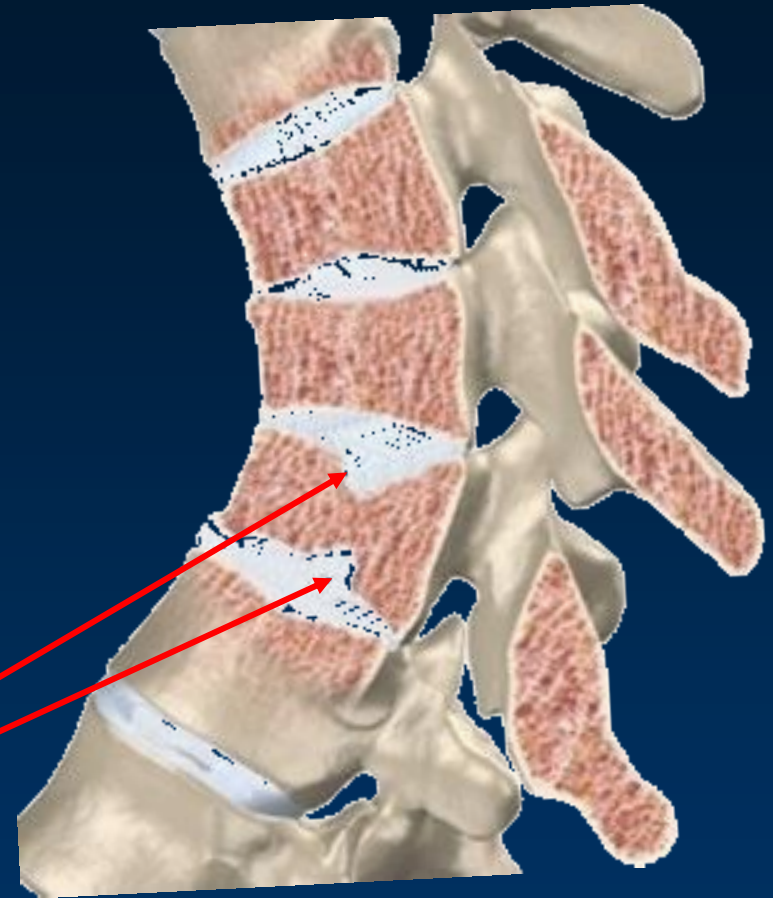
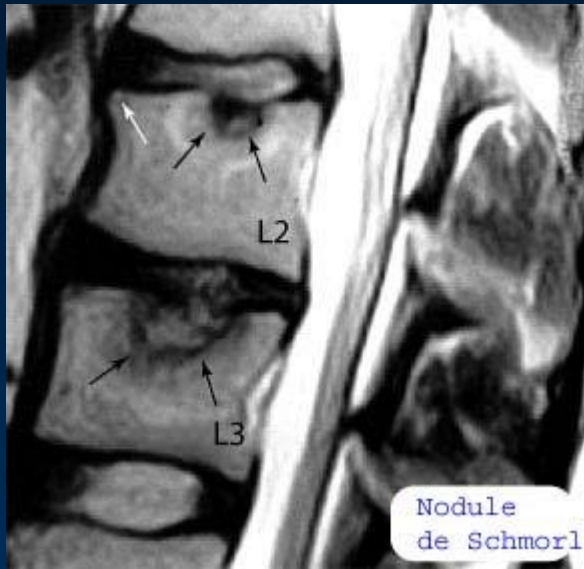
Boys 12 - 18 y

Lower T spine

Schmorl's nods



# M. Scheuermann



Intravertebral disc herniation (40%)

Wedge-shaped deformity

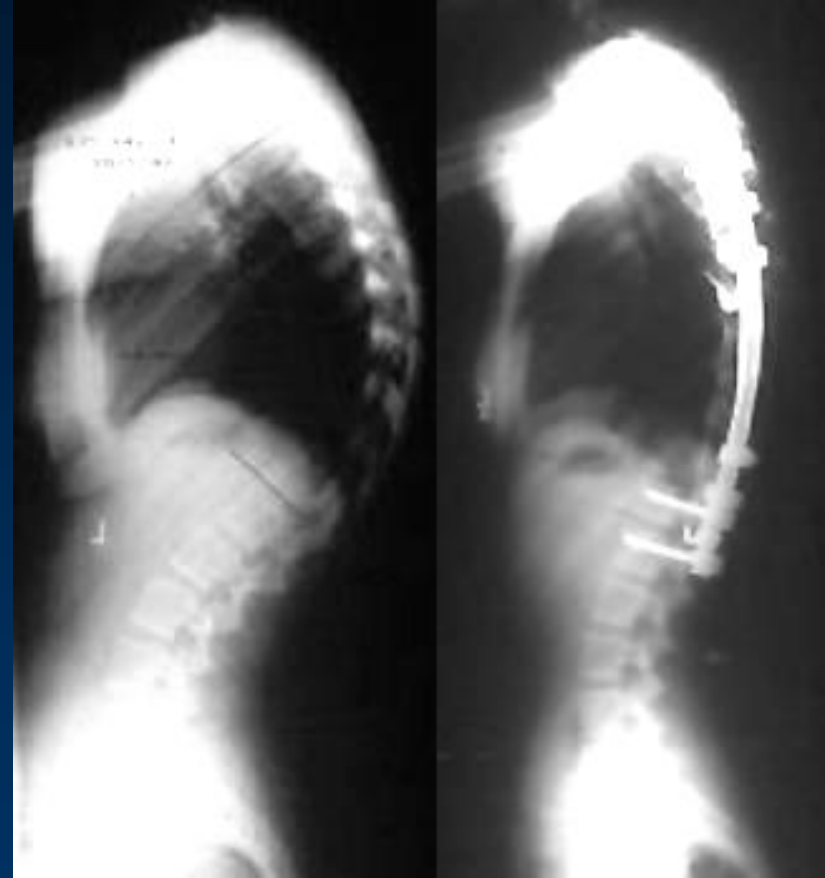
# M. Scheuermann

Kyphosis treatment:

< 40° - activity limitation

> 40° - orthosis

rare surgery



Scoliosis (5)

M. Scheuermann (17)

Spondylosis, spondylarthrosis (27)

Trauma      C1 - 2

subaxial C

T - L

} (51)

Specific + non-specific inflammation (24, 26)